

Second recorded import of the Neotropical Warble Fly, *Dermatobia hominis*, to Finland

Gunilla Ståhls

Ståhls, Gunilla 1995: Second recorded import of the Neotropical Warble Fly, *Dermatobia hominis* (Diptera, Oestridae, Cuterebrinae), to Finland. — Sahlbergia 2:81-82.

The neotropical warble fly, *Dermatobia hominis*, is recorded for the second time from Finland. A female tourist who visited Guatemala had acquired two larvae on her scalp. The life-cycle and the process of host infection are described.

Gunilla Ståhls, Finnish Museum of Natural History, Entomology div., P.O. Box 17, 00014 University of Helsinki

Introduction

The "neotropical warble fly" (also "human bot-fly", "human warble fly", in Finnish "ihmiskiiliäinen", "ihmisen ihosaivartaja"), *Dermatobia hominis* (Diptera, Oestridae, Cuterebrinae) is an important pest on cattle in neotropical America, causing substantial losses to the meat, milk and leather industries. The species is known from all Latin American countries (from the northern provinces of Mexico to the northern Argentine provinces) with the exception of Chile. *Dermatobia hominis* causes myiasis in cattle, but parasitizes also other mammals, birds, and, sometimes humans (Sancho 1988). *Dermatobia hominis* was first imported to Finland in 1989 by a 42-year-old male biologist, who had spent two weeks in Costa Rica (Reunala et al. 1990). This second recorded import to Finland is by a female tourist who visited Guatemala in October 1994.

Life cycle

The life-cycle of *Dermatobia hominis* shows some interesting features. The adult *Dermatobia* flies are metallic blue, about 12-17 mm long (Fig. 1). They have atrophied mouthparts and do not feed, relying on food reserves accumulated during the larval stage. When ready for oviposition, the female *Dermatobia* captures another insect on which to lay her eggs. Especially mosquitoes (Fig. 2) and other blood-sucking insects seem to be suitable as egg carriers. The opaque white eggs, about 1 mm long, are laid in batches of 30-40 on the abdomen of the captive insect, which is then released. Egg survival is dependent on a high local humidity, and hatching is stimulated by the warmth of a mammalian or avian

host on which the carrier insect alights. The first stage larva moves actively on the surface of the vertebrate host and penetrates the host's skin to develop inside a subdermal cavity. For respiration it maintains its entrance hole open to the external air. Inside the cavity the larva feeds and moults twice, burrowing out of the host skin when it reaches the third larval stage (Fig. 3), after 5-10 weeks. The mature larva is about 25 mm long, it leaves its host during the night or early morning, causing damage to the host skin while exiting. The larva falls to the ground, into which it burrows, and pupates. Adults emerge 3-5 weeks later, depending on climate (Sancho 1988 and references therein).

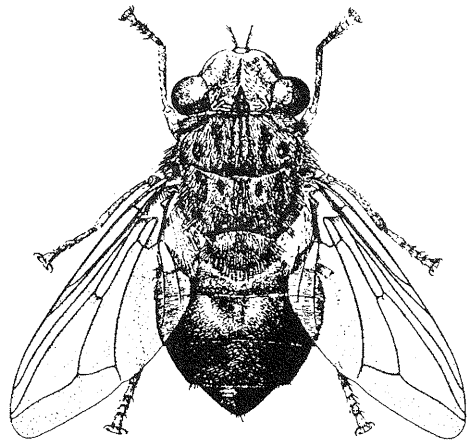


Fig. 1. *Dermatobia hominis*, adult (from Harwood & James 1979).

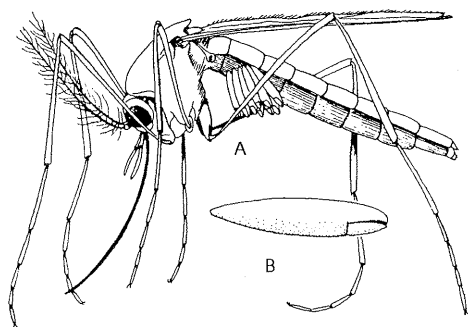


Fig. 2. A. *Psorophora* mosquito carrying a load of *Dermatobia* eggs. B. Egg enlarged (from Harwood & James 1979).

Dermatobia infection

In Latin America human *Dermatobia* infections are most common among cattle workers and among children under five years of age (Sancho 1988 and references therein). *Dermatobia* myiasis is frequently diagnosed in persons (tourists) who have acquired the parasite in tropical America and then returned to their homes in North America and Europe (eg. Gatti et al. 1988, Kaplan 1986, Pape 1991, Schembre et al. 1990, Zollner et al. 1993). The Finnish female tourist had acquired two larvae on her scalp. She never felt the first stage larvae penetrate the skin, this phenomenon is also reported by Harwood & James (1979). The first time she felt pain was after about ten days. The swellings in which *Dermatobia* larva develop were reported to become painful at this point also by Reunala et al. (1990). She also described the sensation of something on her scalp, doctors failed to diagnose. The larvae were finally removed after ca. six weeks, when they had almost reached the third larval stage. After the removal the swellings disappeared, the wound healed quickly and produced no scar. One of the larvae was still alive when brought to the author, but died during the attempt to rear it to an adult. Both larvae are in the collections of the Zoological Museum, Finnish Museum of Natural History.

Acknowledgements. "The female tourist" is thanked for her information on the case. Thomas Pape, Naturhistoriska Riksmuseet, Stockholm, is

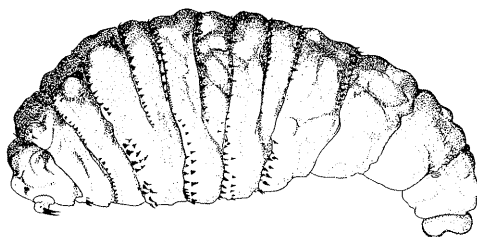


Fig. 3. *Dermatobia hominis*, third instar larva (from Smith 1973).

thanked for the *Dermatobia hominis* bibliography.

Literature

- Gatti, M., R. Giardino, O. Varoli, F. Sommariva & F. Piscolla 1988: One case of cutaneous myiasis from larvae of *Dermatobia hominis*. — *Giorn. Mal. Inf. Parasit.* 40:953-966 (In Italian with English summary).
- Harwood, R. F. & M. T. James 1979: Entomology in human and animal health. — Macmillan, London, 548 pp.
- Kaplan, D. L. 1986: *Dermatobia hominis*: an unwelcome visitor to North Carolina. — *N. Carolina Med. J.* 47:514-516.
- Pape, T. 1991: Faerosk dermatobiose (Diptera: Oestridae, Cuterebrinae) - med en oversigt over human myiasis i Danmark. — *Ent. Meddr.* 59:67-72.
- Reunala, T., L. J. Laine, O. Saksela, T. Pitkänen & K. Lounatmaa 1990: Furuncular myiasis. — *Acta Derm. Venereol. (Stockh.)* 70:167-170.
- Sancho, E. 1988: *Dermatobia*, the neotropical warble fly. — *Parasitol. Today* 4:242-246.
- Schembre, D. F., C. R. Spillert, M. Y. Khan & E. J. Lazaro 1990: *Dermatobia hominis* myiasis masquerading as an infected sebaceous cyst. — *Can. J. Surg.* 33:145-146.
- Smith, K.G.V. 1973: Insects and other arthropods of medical importance. — British Museum of Natural History, London, 561 pp.
- Zollner, C., J. Bayer, E. Langer, A. Keller, A. Resch & P. Stommer 1993: Myiasis in female travellers to the tropics. — *Pathologie* 14:37-41.